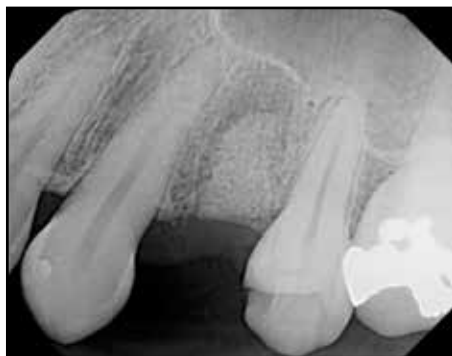

# Inclusive<sup>®</sup> Tapered Implants: 3-Year Follow-Up Study

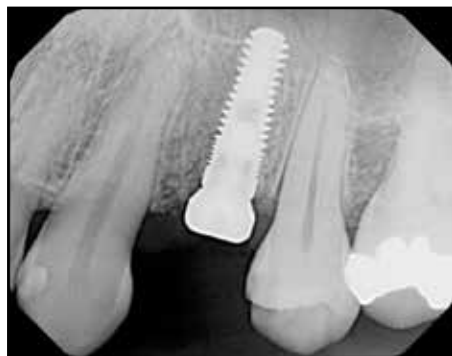by



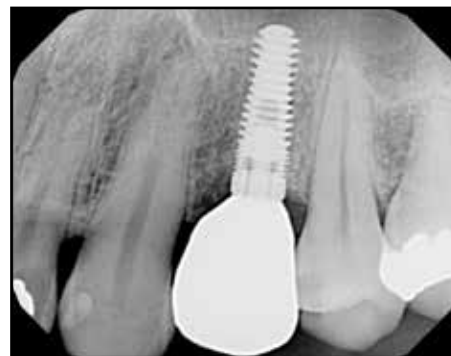# Inclusive<sup>®</sup> Tapered Implants: 3-Year Follow-Up Study



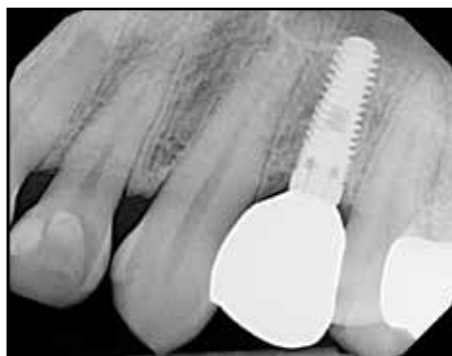Oct. 4, 2011



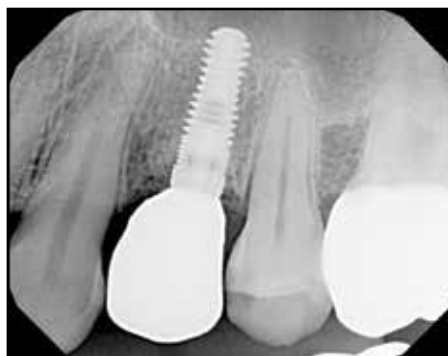Nov. 8, 2011



June 20, 2012



Sept. 30, 2013



Aug. 17, 2015



*by Siamak Abai, DDS, MMedSc*

The long-term viability of dental implants has been proven across countless clinical studies.<sup>1-3</sup> As treatment protocols and fixture designs have progressed, the predictability with which titanium implants can be placed has improved as well.<sup>4</sup> Many studies have suggested a great majority of dental implants in the market today exhibit extremely high success rates, regardless of design or surface preparation.<sup>5,6</sup> Nonetheless, for any clinician considering the use of a particular implant within their practice, it is instructive to compare its performance with that of its peers in order to make an informed decision.

In addition to establishing the foundation for a fixed or removable prosthesis that effectively restores oral function and esthetics, the placement of dental implants serves to mitigate bone loss.<sup>7</sup> The degree to which the alveolar bone is preserved is an important consideration when

selecting a dental implant, as the hard tissue underlying the restoration is key to both long-term function and esthetics.

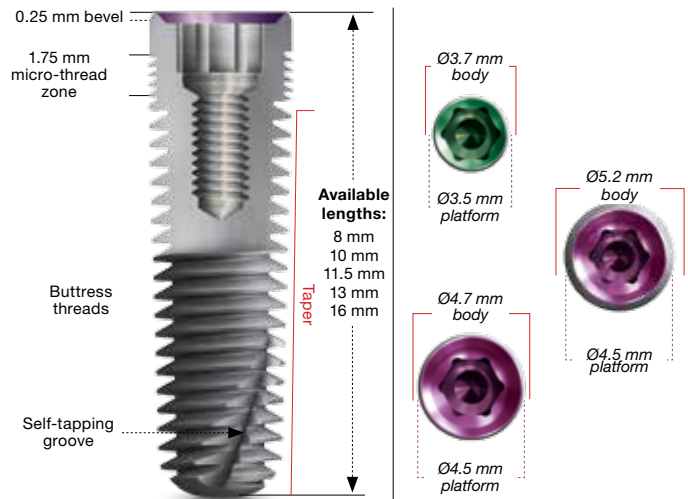
The purpose of this study was to conduct a retrospective analysis of 268 Inclusive<sup>®</sup> Tapered Implants (Glidewell Direct; Irvine, Calif.) placed in human subjects between Sept. 9, 2011, and Feb. 24, 2015, with survival rates and crestal bone loss evaluated at six-month, one-year, two-year, and three-year follow-up periods. The data collected during this study was then compared with results from two of the leading implant systems on the market.

## **Materials and Methods**

This analysis included 268 Inclusive Tapered Implants placed by four practitioners. The operator clinicians were: Siamak Abai, DDS, MMedSc; Darrin M. Wiederhold, DMD, M.S.; Dean H. Saiki, DDS; and Peter M. Scheer DDS, M.S.



**Figure 1:** The dental implants included in this study were placed following the protocol detailed in the Inclusive Dental Implant System Surgical Manual, which can be accessed by visiting the Implants section of [www.glidewell.com](http://www.glidewell.com).



**Figure 3:** Design characteristics, lengths and sizes of the Inclusive Tapered Implant.

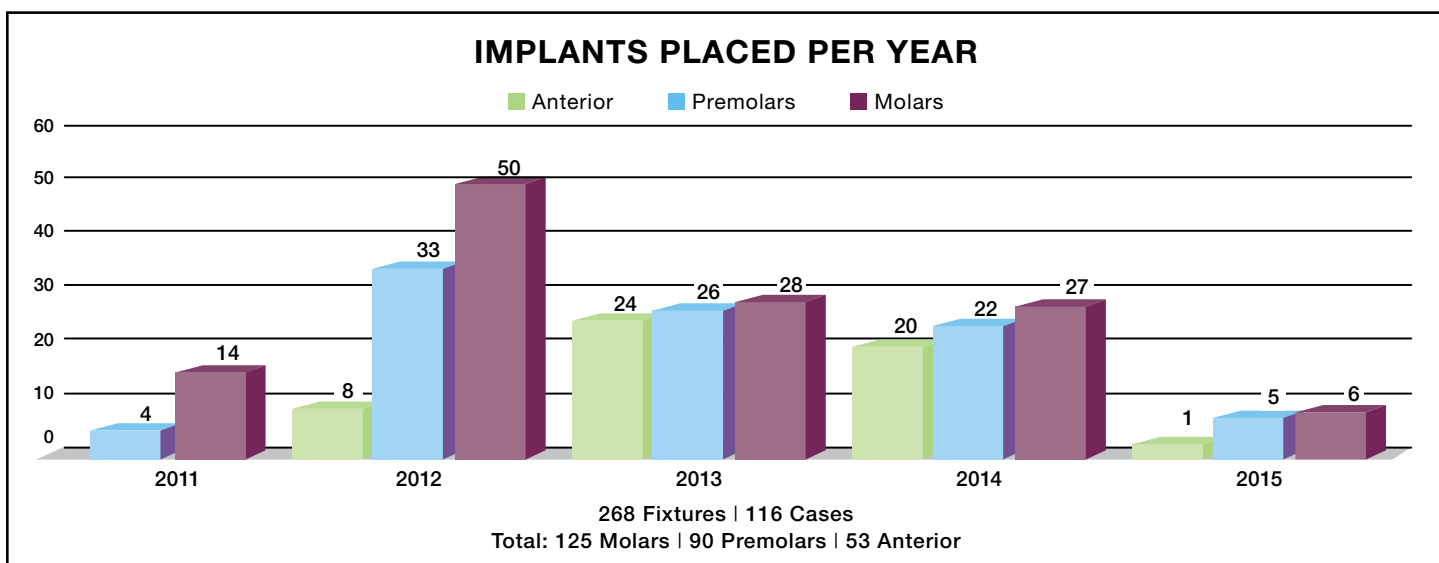
The implants were placed in strict accordance with the protocol detailed in the Inclusive Dental Implant System Surgical Manual, with the support of an experienced surgical team and in adherence with standard sterilization practices (Fig. 1).

There was a total of 116 cases studied including 63 male subjects and 53 females. Of the 268 implants placed, 146 were placed in male subjects, with the remaining 122 placed in females. The 116 cases included single-unit, multiple-unit and full-arch implant restorations. All regions of the arch were represented in this study: 125 of the implants were placed in the molar region, 90 in the premolar, and 53 in the anterior (Fig. 2). Depending on the bone quality and quantity at the implant site and the degree of primary stability achieved, single-stage, two-stage and immediate temporization protocols were observed. Bone grafting was utilized to augment the surgical sites of about 40 percent

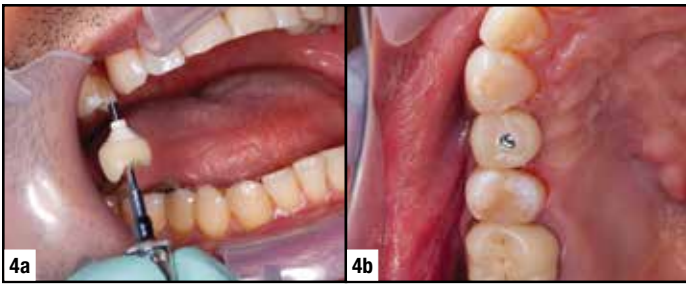of the implants placed.

It should be noted that 29.5 percent of the patients included in this study were smokers at the time of treatment. Recent research has shown typical dental implant failure rates in smokers to be twice that of non-smokers.<sup>8</sup> Provided that 17.8 percent of U.S. adults are classified as smokers, the group of patients included in this study can be considered particularly high-risk.<sup>9</sup>

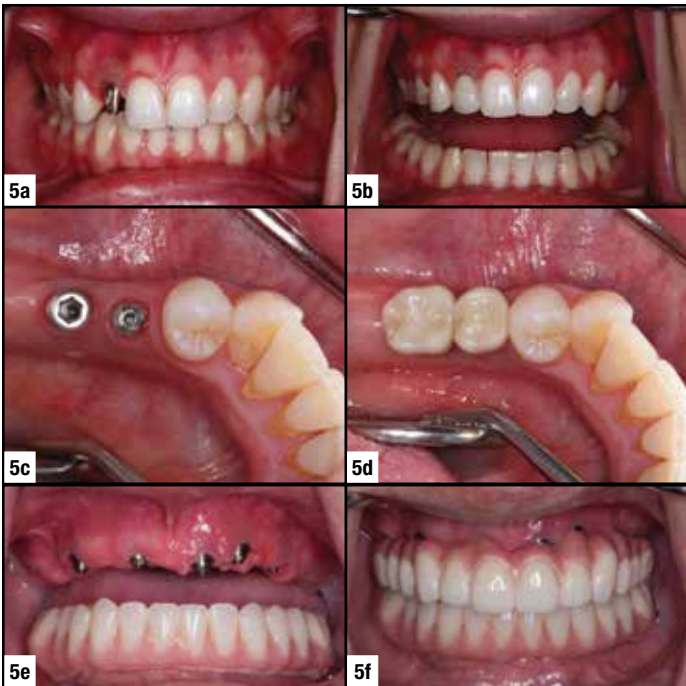
The implants placed in this study included diameters of 3.7 mm, 4.7 mm and 5.2 mm, and lengths of 8 mm, 10 mm, 11.5 mm, 13 mm and 16 mm (Fig. 3). The osteotomies were created with a drill speed of 800–1,200 rpm under continual, copious and sterile irrigation. The manufacturer-recommended sequence of surgical drills was followed per the Inclusive Dental Implant System Surgical Manual.



**Figure 2:** The molar, premolar and anterior regions of the mouth were well-represented throughout the course of this study.



**Figures 4a, 4b:** A screw-retained temporary crown is tightened into one of the many Inclusive Tapered Implants that achieved sufficient primary stability for provisionalization during the course of this study.



**Figures 5a-5f:** The restorations delivered over the three-year period of evaluation ranged from cementable crowns over custom abutments (top), to screw-retained restorations (middle), to full-arch implant restorations (bottom).

After placement of the implants, the patients were monitored via regular follow-up evaluations. Approximately 20 percent of the implants were provisionalized following an immediate loading protocol (Figs. 4a, 4b). The remaining cases were not loaded until delivery of the final prosthesis, which typically occurred within three to 12 months of implant placement. Screw-retained crowns were treatment planned as the final restoration for 200 of the implants included in the study, cementable crowns for 26 of the implants, and fixed or removable full-arch implant prostheses for 42 of the implants (Figs. 5a-5f).

The patient's data, including disease history and health issues that could contribute to implant complications, were documented at the time of initial consultation. Implant failures were promptly recorded, and the patient was treated with replacement implants where indicated. Implant survival rates were reported by quadrant and tooth type. While



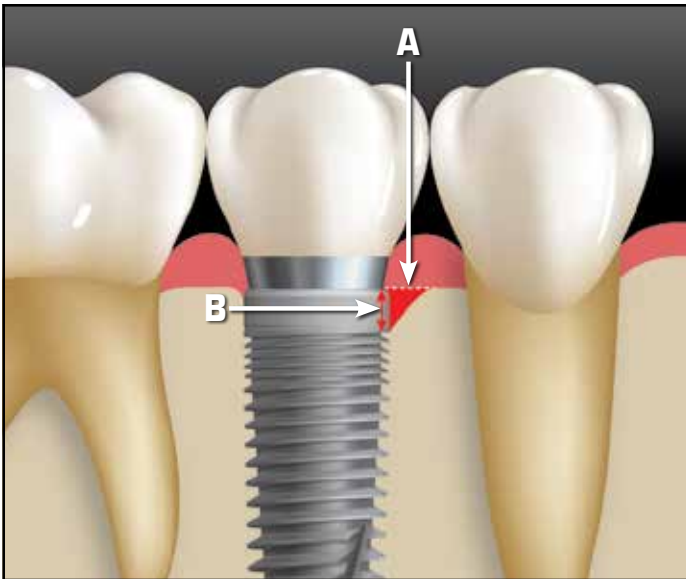
**Figure 6:** A three-year retrospective crestal bone loss study was conducted by evaluating follow-up radiographs taken using the NOMAD Pro handheld X-ray system.

survival rates were reported for all 268 implants included in the study, radiographic bone loss measurements were taken exclusively for patients with implants in place for a minimum of three years at the time of evaluation. Patient participation also depended upon availability of follow-up radiographs.

For the patients included in the crestal bone loss analysis portion of the study, periapical radiographic evaluations were conducted approximately six months following implant placement and then at one-year, two-year and three-year follow-up intervals. The radiographs were taken using a NOMAD Pro™ handheld X-ray system (Aribex, Inc.; Charlotte, N.C.) with exposure settings of 60 kVp and 2.5 mA (Fig. 6). Extraoral alignment instruments were used to ensure consistency across the radiographs included in the study. Crestal bone loss was defined as the amount of vertical bone resorption observed mesial and distal to the shoulder of the implant. The bone loss measurements were determined using DEXIS imaging software (DEXIS; Alpharetta, Ga.). The measurements were performed by dental operatory staff and overseen and verified by the author of this study.

To determine the amount of bone loss exhibited in each radiograph, the crestal-most location of the alveolar bone adjacent to the implant shoulder was marked, and a line perpendicular to the implant was drawn between that point and the mesial or distal surface of the implant. Then, the vertical distance between the first point of current bone-implant contact and the line marking the crestal-most location was measured in millimeters to determine the amount of crestal bone loss (Fig. 7). For each follow-up X-ray, whichever calculation was largest between the mesial and distal crestal bone loss measurements was selected for inclusion in the radiographic portion of the study (i.e., the smaller measurement was excluded when determining the incremental bone loss averages).

After calculating the measurements for the patients included in the radiographic portion of the study, mean crestal bone loss was determined at the six-month, one-year, two-year and three-year follow-ups. Radiographs that were taken between the established follow-up increments were rounded to the closest time period reported (e.g., 10-month radiographs were included in the one-year measurements). The number



**Figure 7:** The amount of crestal bone loss was calculated by drawing a line perpendicular to the implant at the apex of crestal bone adjacent to the mesial or distal surface of the implant, and then measuring from that point to the first instance of current bone-implant contact.

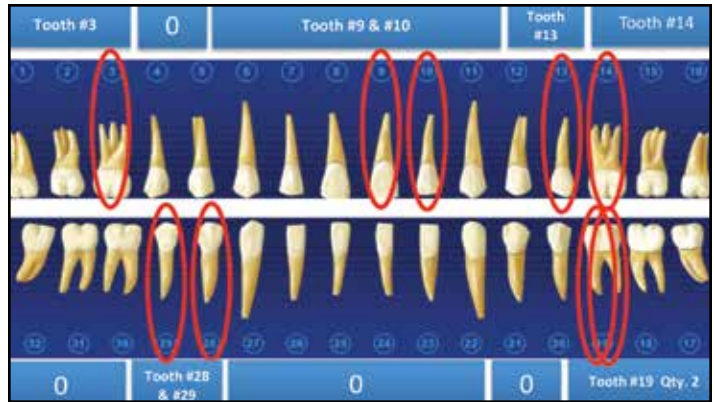
- A:** Apex of crestal bone adjacent to the implant
- B:** Distance (mm) between crestal bone apex and first point of bone-implant contact

of patients studied in each interval varied depending on the time of implant placement relative to the time of study, as well as the frequency of follow-up radiographs. This resulted in the inclusion of 54 patients in the six-month follow-up measurements, 48 in the one-year, 37 in the two-year, and 42 in the three-year.

After determining the implant survival rates and mean crestal bone loss for the established follow-up time periods, these measurements were compared with those of the Zimmer Screw-Vent® implant system (Zimmer Dental; Carlsbad, Calif.) and the NobelReplace® implant (Nobel Biocare; Yorba Linda, Calif.), citing studies similar in scope and objective.

## Results

The overall survival rate for the 268 Inclusive Tapered Implants included in this study was 96.6 percent. Eight of the nine implants that failed did so within six months of placement, with the remaining failure occurring 10 months after placement. This resulted in survival rates of 97 percent at six months, and 96.6 percent at the one-year, two-year and three-year follow-up intervals. Five of the implants that failed had been placed in female patients, and four in males. One failure was reported in the upper right quadrant, four in the upper left, two in the lower left, and two in the lower right. Four of the failures were in the molar region of the patient's mouth, three were premolars, and two were maxillary incisors (Fig. 8).



**Figure 8:** Of the 268 Inclusive Tapered Implants placed in this study, nine failed, including four in the molar region, three in the premolar, and two in the anterior.

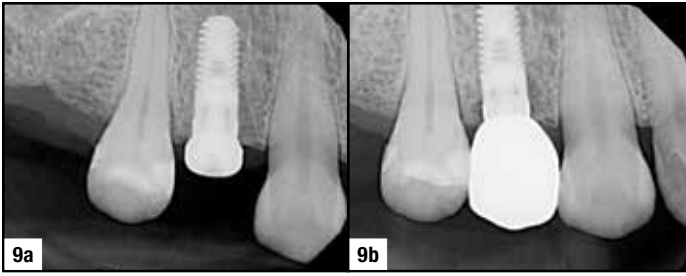
Four of the nine implants that failed had been placed in sites that were grafted at the time of surgery. Two of the nine implant failures occurred in a patient who is a regular smoker with high blood pressure, while the other seven patients presented for treatment without any notable health issues. Eight of the failed implants were placed in single-stage surgical procedures, and the other was placed following a two-stage clinical protocol. Three of the cases that failed were temporized at the time of implant placement.

The mean crestal bone loss observed via radiographic measurement was 0.54 mm after six months (Figs. 9a, 9b). At one year, the mean bone loss was 0.65 mm. (Figs. 10a, 10b). Two years after placement, the mean crestal bone loss was 0.49 mm (Figs. 11a–11c). Mean crestal bone loss at the final three-year follow-up interval was 0.56 mm (Figs. 12a–12d). The highest level of crestal bone loss observed was 2.5 mm at the six-month follow-up, 2.9 mm at the one-year, 1.9 mm at the two-year, and 1.7 mm at the three-year.

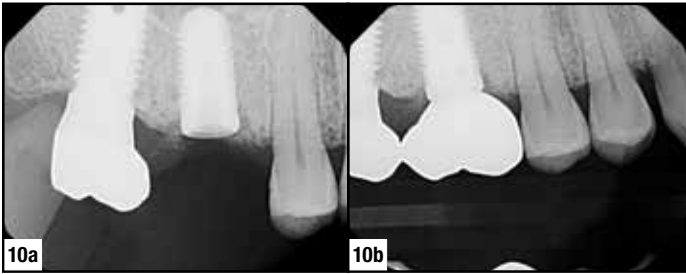
## Discussion

The results of this retrospective analysis demonstrate that the Inclusive Tapered Implant performs well across the full spectrum of restorative indications, including screw- and cement-retained crowns, multi-unit bridges, and fixed and removable full-arch prostheses. The small number of failures and the minimal crestal bone remodeling observed illustrate the implant's suitability as a long-term solution for tooth replacement.

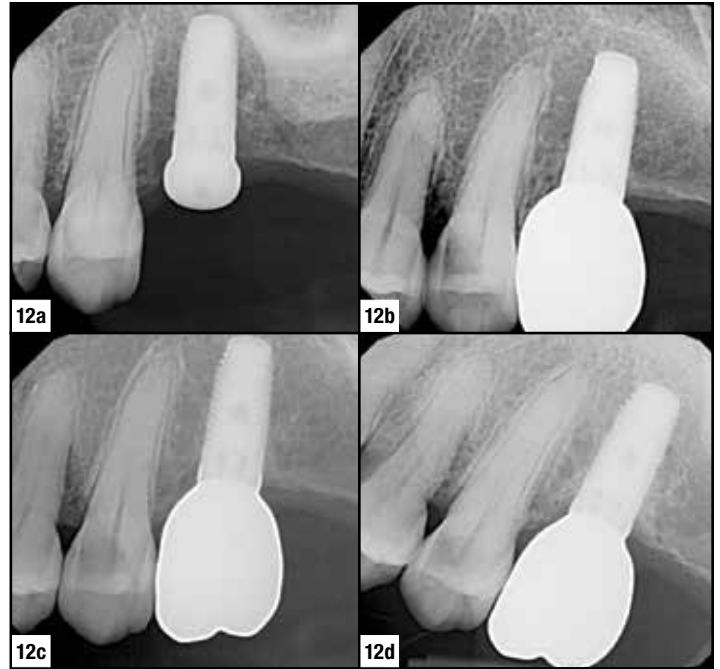
The survival rates and mean crestal bone loss observed in this evaluation are within the range of those reported in studies examining the performance of the Zimmer Screw-Vent and NobelReplace implant systems. The one-, two- and three-year survival rate of 96.6 percent for the Inclusive Tapered Implant coincides with the one-year survival rate of 96.7 percent observed in a one-year study and the 96.6 percent rate reported in a three-year study on the NobelReplace



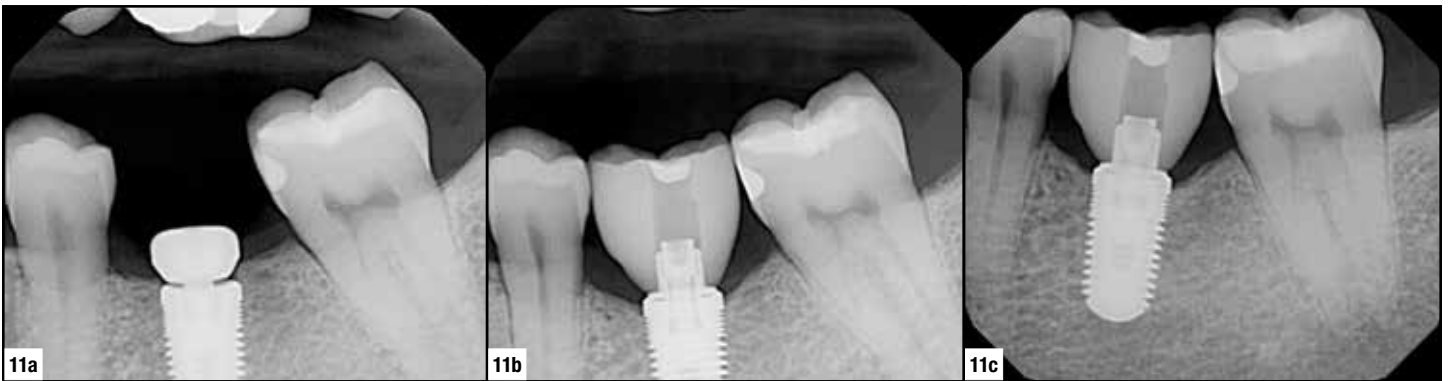**Figures 9a, 9b:** Example of post-placement and six-month follow-up radiographs illustrates effective crestal bone preservation fostered by the Inclusive Tapered Implant in the area of tooth #19.



**Figures 10a, 10b:** This example in the area of tooth #3 exhibits negligible bone remodeling between the time of implant placement and one-year follow-up.



**Figures 12a–12d:** The post-placement, one-year, two-year and three-year radiographs for this patient illustrate long-term integration of the Inclusive Tapered Implant with the bone of the restoration site.



**Figures 11a–11c:** Post-placement, six-month crown delivery, and two-year follow-up radiographs for a case example in the area of tooth #19.


dental implant system.<sup>10,11</sup> Similarly, these findings correspond closely with the performance of the Zimmer Screw-Vent implant, which demonstrated a 97.6 percent success rate in one three-year study and a 98.6 percent rate in a separate two-year study.<sup>12,13</sup>

Likewise, the crestal bone loss measurements observed in the radiographic portion of this study were in line with those demonstrated by leading competitors. The mean crestal bone loss of 0.65 mm exhibited by the Inclusive Tapered Implant at the one-year follow-up parallels the average marginal bone resorption of 0.64 mm observed in a one-year analysis of the NobelReplace implant system.<sup>14</sup> In a study on the Zimmer Screw-Vent implant, the mean marginal bone resorption after two years was 1.66 mm, compared to 0.49 mm of crestal bone loss exhibited by the Inclusive Tapered Implant at the two-year follow-up.<sup>13</sup>

The mean crestal bone loss of 0.56 mm observed for the Inclusive Tapered Implant after three years corresponds to the findings of a three-year analysis of the NobelReplace implant, which exhibited 1.32 mm of bone remodeling.<sup>11</sup>

For the full-time smokers included in this study, the survival rate observed at the three-year follow-up was 97.5 percent and consistent with the results for non-smoking patients. This survival rate is remarkable considering the substantial risk associated with placing dental implants in patients who are smokers, as well as the fact that the patients included in this study were much more likely to smoke (29.5 percent of participants) than the general U.S. population (17.8 percent are smokers).

These findings are in keeping with studies on resorbable blast media (RBM), which conditions the Inclusive Tapered



**Figures 13a, 13b:** The buttress thread design and RBM surface of the Inclusive Tapered Implant are essential in maximizing bone-implant contact and promoting the favorable osseointegration exhibited in this study.

Implant surface and is one of the most highly researched treatments on the market (Figs. 13a, 13b). The RBM surface treatment maximizes bone-implant contact and has been shown to promote bone development on the implant.<sup>15,16</sup> Further, the survival rates and crestal bone preservation observed confirm the effectiveness of the implant's tapered shape and buttress-thread design, which were engineered to engage the bone and aid the osseointegration process.

## Conclusion

For practitioners comparing the many implant systems available on the market today, the Inclusive Tapered Implant is a suitable treatment option that facilitates both bone preservation and survival rates within the range of those offered by leading competitors. The similarity in performance between the Inclusive Tapered Implant and the industry-leading implants selected for comparison confirms it to be a predictable, versatile system that can be utilized with confidence in a full range of clinical indications and protocols. The radiographic observations made during the course of this study show that in addition to excellent survival rates, the implant also preserves bone effectively, which is key to both esthetics and function over the long term.

## References

- Barrachina-Diez JM, Tashkandi E, Stampf S, Att W. Long-term outcome of one-piece implants. Part I: implant characteristics and loading protocols. A systematic literature review with meta-analysis. *Int J Oral Maxillofac Implants.* 2013 Mar-Apr;28(2):503-18.
- Moraschini V, Poubel LA, Ferreira VF, Barboza Edos S. Evaluation of survival and success rates of dental implants reported in longitudinal studies with a follow-up period of at least 10 years: a systematic review. *Int J Oral Maxillofac Surg.* 2015 Mar;44(3):377-88.
- Pjetursson BE, Thoma D, Jung R, Zwahlen M, Zembic A. A systematic review of the survival and complication rates of implant-supported fixed dental prostheses (FDPs) after a mean observation period of at least 5 years. *Clin Oral Implants Res.* 2012 Oct;23 Suppl 6:22-38.
- Pjetursson BE, Asgeirsson AG, Zwahlen M, Sailer I. Improvements in implant dentistry over the last decade: comparison of survival and complication rates in older and newer publications. *Int J Oral Maxillofac Implants.* 2014;29 Suppl:308-24.
- Esposito M, Ardebili Y, Worthington HV. Interventions for replacing missing teeth: different types of dental implants. *Cochrane Database Syst Rev.* 2014 Jul 22;7:CD003815.
- Jokstad A, Braegger U, Brunski JB, Carr AB, Naert I, Wennerberg A. Quality of dental implants. *Int Dent J.* 2003;53(6 Suppl 2):409-43.
- Covani U, Cornelini R, Barone A. Bucco-lingual bone remodeling around implants placed into immediate extraction sockets: a case series. *J Periodontol.* 2003 Feb;74(2):268-73.
- Chrcanovic BR, Albrektsson T, Wennerberg A. Smoking and dental implants: A systematic review and meta-analysis. *J Dent.* 2015 May;43(5):487-98.
- Centers for Disease Control and Prevention. Current Cigarette Smoking Among Adults—United States, 2005–2013. *Morbidity and Mortality Weekly Report* 2014;63(47):1108–12.
- Calandriello R, Tomatis M. Simplified treatment of the atrophic posterior maxilla via immediate/early function and tilted implants: A prospective 1-year clinical study. *Clin Implant Dent Relat Res.* 2005;7 Suppl 1:S1-12.
- Arnhart C, Kielbassa AM, Martinez-de Fuentes R, Goldstein M, Jackowski J, Lorenzoni M, Maiorana C, Mericske-Stern R, Pozzi A, Rompen E, Sanz M, Strub JR. Comparison of variable-thread tapered implant designs to a standard tapered implant design after immediate loading. A 3-year multicentre randomised controlled trial. *Eur J Oral Implantol.* 2012 Summer;5(2):123-36.
- Minichetti JC, D'Amore JC, Hong AY. Three-year analysis of Tapered Screw-Vent implants placed into extraction sockets grafted with mineralized bone allograft. *J Oral Implantol.* 2005;31(6):283-93.
- Khayat PG, Milliez SN. Prospective clinical evaluation of 835 multithreaded tapered screw-vent implants: results after two years of functional loading. *J Oral Implantol.* 2007;33(4):225-31.
- Bassetti R, Kaufmann R, Ebinger A, Mericske-Stern R, Enkling N. Is a grooved collar implant design superior to a machined design regarding bone level alteration? An observational pilot study. *Quintessence Int.* 2014 Mar;45(3):221-9.
- Piattelli M, Scarano A, Paolantonio M, Iezzi G, Petrone G, Piattelli A. Bone response to machined and resorbable blast material titanium implants: an experimental study in rabbits. *J Oral Implantol.* 2002;28(1):2-8.
- Nishimoto SK, Nishimoto M, Park SW, Lee KM, Kim HS, Koh JT, Ong JL, Liu Y, Yang Y. The effect of titanium surface roughening on protein absorption, cell attachment, and cell spreading. *Int J Oral Maxillofac Implants.* 2008 Jul-Aug;23(4):675-80.



Designed & Manufactured in the USA  
by



4141 MacArthur Blvd.  
Newport Beach, CA 92660 USA